

Research Reporting Standards for Endovascular Treatment of Pelvic Venous Insufficiency



Carl M. Black, MD, Kelly Thorpe, NP, Anthony Venrbux, MD, Hyun S. Kim, MD, Steven F. Millward, MD, Timothy W. I. Clark, MD, MSc, Sanjoy Kundu, MD, Louis G. Martin, MD, David Sacks, MD, John York, MD, and John F. Cardella, MD

J Vasc Interv Radiol 2010; 21:796–803

Abbreviations: PCS = pelvic congestion syndrome, PVI = pelvic venous insufficiency, QOL = quality of life, VAS = visual analog scale

THIS document is the product of a cooperative effort by the Society of Interventional Radiology (SIR) Technology Assessment Committee. Adoption of common definitions, approaches to diagnosis and treatment, and clinical out-

comes assessment is expected to help optimize the care of patients with chronic pelvic pain resulting from pelvic venous insufficiency (PVI). The purpose of this research reporting standards document is to improve the quality and relevance of PVI research by providing guidelines for the design and reporting of clinical trials.

Chronic pelvic pain is a common health problem among women and is defined as noncyclic pelvic pain of more than 6 months' duration. The condition is potentially debilitating, and afflicts millions of women worldwide. It has been reported that as many as 39% of women experience chronic pelvic pain at some time in their lives (1). Chronic pelvic pain presents a common challenge for providers of women's care, including obstetricians and gynecologists, family physicians, emergency room physicians, internists, surgeons, gastroenterologists, and pain management physicians.

Unfortunately, PVI is often overlooked in the differential diagnosis of pelvic pain. The routine diagnostic workup in as many as one third of all patients who are evaluated for chronic pelvic pain will yield no obvious etiology. Of these patients in whom there is no apparent cause of pelvic pain, an estimated 30% have PVI (2). PVI is anatomically analogous to the male varicocele, but because the associated pelvic varicosities are often not externally visible or palpable, the diagnosis may be elusive. Pelvic congestion with pelvic

varices was first described in 1857 and the first association of PVI with chronic pelvic pain was described in 1949 (3,4). Although an association of pelvic venous congestion with a psychosocial condition has been described (5,6), the anatomic hemodynamic mechanism resulting in physical symptoms has also been well documented. Retrograde flow through incompetent gonadal and pelvic veins may result in painful pelvic varicosities (4,7). Because of the negative psychosocial associations historically associated with the traditional term of pelvic congestion syndrome (PCS), PVI is now the preferred term as it defines the pathophysiology of the condition. The psychological factors often described with PCS are likely the result of, rather than the cause of, symptoms related to PVI (8). In addition to psychotherapy, multiple approaches to the management of symptomatic pelvic venous congestion have been described, including hormonal suppression, hysterectomy and oophorectomy, and transcatheter embolization.

Hormonal suppression of ovarian function and hysterectomy with bilateral salpingo-oophorectomy are commonly prescribed therapeutic options for PVI. However, studies report only short-term relief, with residual pain in as many as 33% of patients (9–12). In a small pilot study (9), 22 women with pelvic congestion confirmed by venography were treated with medroxyprogesterone acetate for 6 months. At the end of treatment, 18 women had a sig-

From Utah Valley Interventional Associates and Intermountain Vein Center (C.M.B., K.T.), Provo, Utah; Division of Vascular and Interventional Radiology (A.V.), George Washington University Medical Center, Washington, DC; Department of Radiology (H.S.K., L.G.M.), Emory University School of Medicine, Atlanta, Georgia; Department of Radiology (S.F.M.), University of Western Ontario, London; Department of Diagnostic Imaging (S.F.M.), Peterborough Regional Health Centre, Peterborough; Department of Radiology (S.K.), Scarborough General Hospital, Toronto, Ontario, Canada; Section of Interventional Radiology (T.W.I.C.), New York University School of Medicine and New York University Medical Center, New York, New York; Section of Interventional Radiology (D.S.), The Reading Hospital and Medical Center, West Reading; Department of Radiology (J.F.C.), Geisinger Health System, Danville, Pennsylvania; and Medical Corps, United States Navy (J.Y.), Naval Medical Center Portsmouth, Portsmouth, Virginia. Received January 7, 2010; final revision received February 9, 2010; accepted February 17, 2010. **Address correspondence to** C.M.B., c/o SIR, 3975 Fair Ridge Dr., Suite 400 N., Fairfax, VA 22033; E-mail: carl.black@utahradiology.com

The views expressed in the article are those of the authors and do not necessarily reflect the official policy or position of the Department of the Navy, Department of Defense, or the United States Government. T.W.I.C. has a royalty agreement with, and is a paid consultant for, Merit Medical Systems (South Jordan, Utah). None of the other authors have identified a conflict of interest.

© SIR, 2010

DOI: [10.1016/j.jvir.2010.02.017](https://doi.org/10.1016/j.jvir.2010.02.017)

Table 1
Literature Review of Pelvic Venous Embolization (2,14–21)

Study, Year	No. of Pts.	Embolization Target	Embolic Agent	Mean Follow-up (mo)	Clinical Outcome
Kim et al, 2006 (2)	127	106 Bilateral ovarian; 20 unilateral ovarian; 108 internal iliac	Sclerosant and coils	45	Significant relief in 83%; no relief in 13%; worsened in 4%
Edwards et al, 1993 (13)	1	Bilateral ovarian	Coils	6	Significant relief in 100%
Sichlau et al, 1994 (14)	3	Bilateral ovarian	Coils	1 at 14 months, 2 long term	Significant relief in 100%
Tarazov et al, 1997 (15)	6	4 Left ovarian; 1 bilateral ovarian	Coils	12–48	Significant relief in 66.6%; partial relief in 33.3%
Capasso et al, 1997 (16)	19	13 Unilateral ovarian; 6 bilateral ovarian	Coils	15.4	Significant relief in 57.9%; partial relief in 15.8%; no relief in 26.3%
Cordts et al, 1998 (17)	9	4 Left ovarian; 4 bilateral ovarian; 1 obturator	Coils	13.4	Significant relief in 66.7%; partial relief in 22.2%; no relief in 11.1%
Maleux et al, 2000 (18)	41	32 Unilateral ovarian; 9 bilateral ovarian	Glue	19.9	Significant relief in 58.5%; partial relief in 9.7%; no relief in 31.8%
Venbrux et al, 2002 (19)	56	56 Bilateral ovarian; 43 bilateral internal iliac	Sclerosant and coils	22.1	Significant/partial relief in 96%; no relief in 4%
Pieri et al, 2003 (20)	33	1 Right ovarian; 11 left ovarian; 21 bilateral ovarian	Sclerosant	6 and 12	Significant relief in 100%
Bachar et al, 2003 (21)	6	3 Left ovarian; 3 bilateral ovarian	Coils	7.3	Significant relief in 50%; partial relief in 33.3%

nificant reduction in pain with a reduction in venous congestion seen on venography. Efficacy was generally maintained for 3 months after the end of therapy, but at 9 months after treatment, no residual benefit was observed (9).

In another study of 47 patients with isolated pelvic congestion (10), patients were randomized to receive goserelin or medroxyprogesterone acetate for 6 months. The study groups were comparable in age, parity, venographic findings, and pelvic symptom severity scores. All patients had regular menstrual cycles, suggesting normal hormonal function. None were using oral contraception, and none used oral contraceptives after the treatment as an adjunctive measure. Randomization resulted in statistically similar baseline characteristics between groups. Goserelin was more effective than medroxyprogesterone acetate in ameliorating symptoms, but the authors concluded it was unlikely that a temporary artificial menopause of only 6 months would yield lasting relief from PCS (10).

Many gynecologists have resorted to hysterectomy and oophorectomy to

treat PVI (9). In a small observational study of 36 women treated surgically for PCS (11), it was shown that bilateral oophorectomy combined with hysterectomy alleviated chronic pelvic pain resulting from venous congestion during a follow-up period of 1 year. Bilateral oophorectomy in women of reproductive age was performed only as a last resort. The authors concluded that the relief realized after oophorectomy supports its use in women of reproductive age only when all other methods of treatment have failed. Other factors that influenced the decision included duration of pain and age and parity of the patient (11).

Embolization for the treatment of PVI is defined as the injection of embolic material into incompetent pelvic varices under imaging guidance. Since the first description of embolization for the treatment of PCS in 1993 (13), several case reports and series (2,13–22) have reported that embolization offers an effective, minimally invasive, safe therapeutic option with greater than 95% technical success rate and significant relief of symptoms in 68%–

100% of patients with mean clinical follow-up ranging from 1 to 48 months (Table 1) (2,14–22). A single small prospective randomized trial (23) compared embolization versus combined hysterectomy and oophorectomy or hormonal ovarian suppression. Embolization was found to be significantly more effective at reducing pelvic pain in PCS. Although various approaches to treatment have been employed, the emerging treatment of choice is transcatheter ovarian and pelvic venous embolization. The purpose of this document is to create clinically relevant guidelines for reporting outcomes of clinical trials of endovascular treatment of symptomatic PVI.

TERMINOLOGY AND DEFINITIONS

Standardized definitions should be used to describe the anatomic extent and clinical severity of symptomatic PVI. The following definitions are widely accepted by the general medical community.

Pelvic venous congestion syndrome, or

PCS, refers to a condition of chronic pelvic pain of greater than 6 months' duration secondary to PVI and associated pelvic venous distension. It usually presents as lower back pain and heaviness in the lower pelvis, vulvar region, and upper thighs. The pain is typically exacerbated with menses and may be associated with dyspareunia and prolonged postcoital discomfort. Symptoms are generally most severe at the end of the day and are diminished with supine positioning (24).

PVI refers specifically to the pathophysiology of retrograde flow through incompetent gonadal and pelvic veins. The etiology of PVI is multifactorial, and includes factors such as primary valvular insufficiency, venous outflow obstruction, and hormonally mediated vasomotor dysfunction. Retrograde flow through incompetent gonadal and pelvic veins is often—but not uniformly—associated with painful pelvic varicosities (4,7). Because of the negative psychosocial associations historically associated with the traditional term of PCS, PVI is now the preferred term as it defines the anatomic pathophysiology of this condition.

POPULATION DESCRIPTION

Affected patients typically present in their late twenties or early thirties with a history of chronic pelvic pain of greater than 6 months' duration. The classic and almost pathognomonic presentation includes varying degrees of positional pelvic and lower back pain exacerbated by prolonged standing and strenuous activity. The pain is often described as heaviness and fullness in the lower pelvis, vulvar region, and thighs. The pain is typically exacerbated with menses and may be associated with dyspareunia and prolonged postcoital discomfort. Symptoms are typically most severe at the end of the day. Patients frequently describe the pain to be diminished with supine positioning and often experience the most relief upon awakening in the morning (24). The combination of postcoital ache and ovarian point tenderness is reported to be 94% sensitive and 77% specific for the diagnosis of PVI when confirmed by venography (25). Patients may present with atypical nonsaphenous pudendal, vulvar, and perilabial varicosities that are visible on physical examination. Incom-

petent pelvic varices also often collateralize into posterolateral thigh and gluteal regions (8,26). An increased incidence of symptomatic PVI has been reported in patients with complex nonsaphenous patterns of lower-extremity superficial venous insufficiency (27).

Pathophysiology

The left ovarian plexus drains into the left ovarian vein, which typically empties into the left renal vein. The right ovarian vein usually drains directly into the inferior vena cava. On the left there may be an uncommon but well recognized communication between the gonadal vein and the portal venous system via the inferior mesenteric vein. In addition, there may be collateral communication between the ovarian plexus and the internal iliac veins. The internal iliac veins also drain obturator, internal pudendal, and gluteal veins. Mean values of ovarian venous diameter, 10 mm from the origins, are 3.8 mm in the presence of competent valves and 7.5 mm when the valves are incompetent. The upper limit of normal for ovarian veins is 5 mm, with the right usually somewhat larger than the left. Women with ovarian venous diameters of greater than 8 mm have significantly wider periuterine veins than those in whom the ovarian venous diameter is less than 8 mm (28). Although venous dimensions may help in confirming the diagnosis of PVI, it is the authors' opinion that strict diameter measurements should not preclude treatment if the overall clinical picture suggests PVI.

The etiology of PVI is multifactorial, including factors such as primary valvular insufficiency, venous outflow obstruction, and hormonally mediated vasomotor dysfunction. Several studies of the pelvic vasculature in women have focused on the mechanical theory for PVI. The mechanical theory of congestion suggests that dilation of ovarian veins results in vascular incompetence and retrograde venous flow. Anatomic studies have shown that as many as 15% of female subjects lack valves in the cephalad segment of the left ovarian vein and 6% lack cephalad valves on the right. Valves, even when present, are incompetent on the left in as many as 43% of patients and on the right in as many as 41% (29).

The frequency of incompetent valves and the diameter of the gonadal veins are significantly greater in multiparous women compared with the nulliparous population. It is postulated that the chronic venous distension that occurs during pregnancy can render valves incompetent as the vascular capacity of the ovarian veins expands by as much as 60-fold during pregnancy (14). Venous outflow obstruction from anomalous anatomic variants such as a retroaortic left renal vein and meso-aortic compression of the left renal vein may also contribute to secondary PVI.

Disturbances of hormonal vasomotor regulation also factor into the development of PVI. In studies of oophorectomized mice, the uterine and ovarian veins have been shown to selectively enlarge in response to estradiol or testosterone administration without any change in the femoral or iliac vein or inferior vena caval dimensions. This animal-based model suggests that uterine and ovarian veins have disproportionate sensitivity to ovarian-produced hormones. During a normal menstrual cycle, the ovarian veins are exposed to a nearly 100-fold higher concentration of estrone and estradiol compared with peripheral plasma (29). The resulting ovarian venous distension is thought to exacerbate the symptoms of PVI. This concept is supported by the observation that the signs and symptoms of PVI are exacerbated with menstruation and pregnancy and generally diminish with menopause. This concept is also supported by reports of decreased pain associated with PVI following pharmacologic ovarian suppression (24,25).

Diagnostic Evaluation

Although there have been many advances in cross-sectional imaging, catheter-directed venography remains the gold standard in confirming the suspected clinical diagnosis of PVI. Cross-sectional imaging is typically performed before venography to exclude a concurrent pelvic pathologic process. Venographic evaluation should include assessment of the inferior vena cava, the left renal vein, the gonadal veins, and the common and internal iliac veins. Proposed diagnostic criteria for PVI on venography include ectasia with diam-

eters of at least 5 mm in the ovarian, uterine, and uteroovarian arcade veins; free reflux in the ovarian vein with valvular incompetence; contralateral reflux of contrast medium across the midline; opacification of vulvar or thigh varices; and stagnation of contrast medium in pelvic veins (2,28,30,31). As previously stated, although absolute venous dimensions may help in confirming the diagnosis of PVI, it is the authors' opinion that strict diameter measurements should not preclude treatment if the overall clinical picture otherwise suggests PVI.

The primary goal and utility of ultrasound (US), magnetic resonance (MR) imaging, computed tomography (CT), and laparoscopy in the workup of PVI is to exclude a concurrent pelvic pathologic process. Although cross-sectional imaging may demonstrate pelvic venous ectasia, these modalities are limited by low sensitivity with limited published data comparing laparoscopy, US, CT, and MR imaging against the generally accepted gold standard of catheter-directed venography. The overall low sensitivity of cross-sectional imaging in diagnosing pelvic varices may in part reflect supine positioning, which decompresses the relevant veins. In a study of 139 patients with clinical findings of pelvic insufficiency (31), pelvic varices were demonstrated in only 53% of patients by transabdominal and transvaginal US. Although CT and MR imaging can demonstrate pelvic varices (32,33), published experience is limited and lacks correlation with venography.

Multiplanar pelvic MR imaging with MR venography may allow exclusion of uterine and ovarian pathologic processes, endometriosis, adenomyosis, and lumbosacral disease, and the anatomic information obtained from the MR venography study has also been described as useful in assisting preprocedural planning before embolization (34). It is estimated that as many as 80% of pelvic varices go undetected by laparoscopy as a result of technical limitations, which include compression of the varices from peritoneal CO₂ insufflation and the resultant decompression of varices while the patient is in Trendelenburg position (30). In a longer-term, 2-year study of 131 patients with a confirmed diagnosis of PCS (2), the sensitivities of MR imaging, laparoscopy, US, and CT

were found to be 58.6%, 40%, 20%, and 12.5%, respectively. The investigators found no difference in clinical outcomes from embolization for PVI between those patients who had positive preembolization cross-sectional imaging findings or directly visualized pelvic varices by laparoscopy compared with those with negative laparoscopy and preembolization venographic imaging findings. The authors attributed this observation to relatively low sensitivities for MR imaging, laparoscopy, US, and CT (2). Reporting of preprocedural diagnostic imaging findings should include venographic findings in all patients and related findings demonstrated by US, CT, MR imaging, and laparoscopy.

Recommended population description data to be collected include age, ethnicity, obstetric history, details of previous treatments, comorbidities, disease severity and duration of symptoms, quality of life (QOL) assessment, physical findings, imaging findings, treatment indications, inclusion criteria, exclusion criteria, and method of assigned treatment.

TREATMENT DESCRIPTION

As a point of informational reference, we describe a basic approach to embolotherapy. Embolization techniques used in the management of PVI are subject to ongoing refinement and evaluation through appropriately designed studies. Embolization is generally performed on an outpatient basis. Access to gonadal and internal iliac pelvic veins is traditionally gained via a transjugular or transfemoral route, depending on operator experience and preference. After gonadal venous insufficiency is confirmed by venography, transcatheter embolization is performed. The ovarian veins typically have multiple tributaries that generally collateralize into the uteroovarian venous arcade with contralateral reflux of contrast medium across the midline. There often is opacification of vulvar or thigh varices and stagnation of contrast medium in pelvic veins. Incomplete embolization of the gonadal vein tributaries and associated pelvic collateral vessels may be a source of clinical failure.

The goal of embolization is to eliminate the hydrostatic pressure generated from gonadal and pelvic collateral ve-

nous insufficiency. Foamed sclerosant combined with Gelfoam (Pharmacia & Upjohn, Kalamazoo, Michigan) are often used as adjuncts to coil embolization and have been reported to reduce recanalization and treatment failure (2). Commonly used sclerosant agents include 3% sodium tetradecyl sulfate (Bioniche Teo; Inverin, Galway, Ireland) and 5% sodium morrhuate (American Regent Laboratories, Shirley, New York). The volume of sclerosant to be injected can be estimated based on a preliminary contrast agent injection into the cross-pelvic varices. To avoid non-target embolization, it may be appropriate to use a volume of embolic agent equal to or less than the volume of the contrast agent test injection. Coil embolization is then performed of the main gonadal vein and each of its principal tributaries to a level of approximately 3 cm from the left renal vein or IVC on the right. Coils should be oversized to optimize stability and prevent migration. Gonadal vein embolization is then followed by repeat left renal venography from the renal hilum to confirm gonadal vein occlusion, and venography of the inferior vena cava is performed after embolization of the right ovarian vein to confirm occlusion. Bilateral venography should then be carried out in the internal iliac veins to assess for residual collateral flow into ovarian, vulvar, or thigh-region varices. Selective embolization can then be carried out in a similar fashion. Coaxial temporary balloon occlusion may be helpful to control flow during embolization. Coils should be used with caution in the internal iliac branches as there is increased potential for coil migration (2,19). Postembolization internal iliac venography is then performed to confirm anatomic success.

Reported procedure details should include sources of PVI, target veins for embolization, route of venous access, embolic material, procedure duration, sedation requirements, and periprocedural medications. In addition, postembolization venographic findings should be reported.

Concomitant Treatments

Concomitant percutaneous US-guided sclerotherapy of nonsaphenous pudendal varices may play a supplemental role in the endovascular treatment

of PVI; therefore, an effort should be made to develop prospective therapy regimens or algorithmic approaches to treatment such that their role as confounding variables is limited. Data should be collected and reported regarding all adjunct procedures and medical/drug treatments. Use of adjunctive therapies not included in the original protocol should be reported as deviations and considered failures on an intent-to-treat basis.

OUTCOMES ASSESSMENT

Treatment decisions regarding endovascular therapies for the treatment of PVI will likely be based on the concept that the increased risk to the patient associated with a more invasive alternative treatment may be justified if the benefit to the patient outweighs the risk. Therefore, rigorous collection of safety and efficacy outcome measures is essential. When reporting clinical trial results, the measures that are primary and those that are secondary should be clear and prospectively established. Attempts should be made to choose primary endpoints that have the most direct clinical relevance and would be the most meaningful to consider in future treatment decisions. Surrogate primary efficacy endpoints should be avoided when possible.

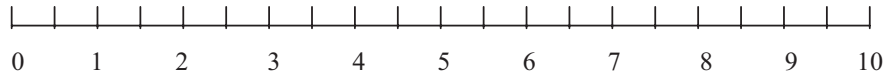
The timing and results of clinical follow-up should be reported, as well as personnel responsible for this. The type, timing, and results of imaging follow-up should also be reported. Assessment of treatment efficacy/clinical success is crucial when reporting the results of endovascular treatment of PVI. It is important to describe and define how all tools/metrics are used to objectively assess clinical status after intervention when compared with preprocedural measurements/status.

The primary clinical endpoint in the study of pelvic venous embolization is to improve a patient's QOL through relief of chronic pelvic pain. Clinical benchmarks to be reported before and after treatment of PVI include overall pelvic pain level, pelvic and leg pain on standing, pelvic and leg pain on lying down, dyspareunia, menstrual pain, increased urinary frequency, and the use of pain medication. A validated visual analog scale (VAS) should be employed to quantify the patient's preintervention baseline

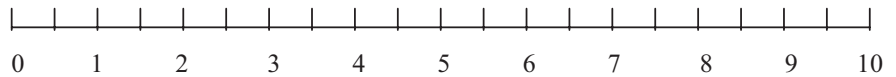
Name: _____ D.O.B. _____ Date: _____

Please mark the scale below to measure the intensity of your discomfort. A zero (0) means no pain and a ten (10) means extreme pain.

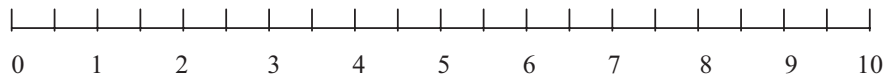
How **intense** is your overall pelvic pain?



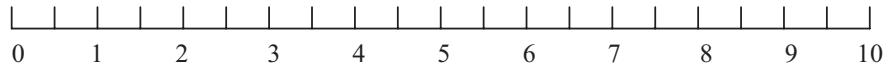
How **intense** is your pelvic pain while lying down?



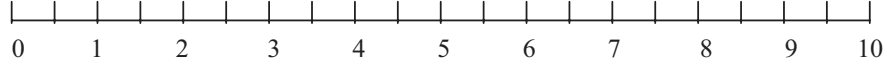
How **intense** is your pelvic pain while standing?



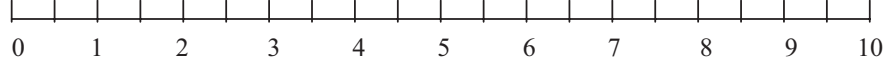
How **intense** is the pain in your leg(s) while lying down?



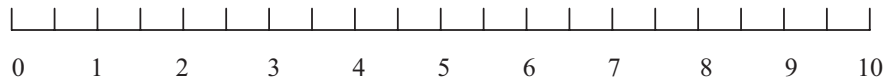
How **intense** is the pain in your leg(s) while standing?



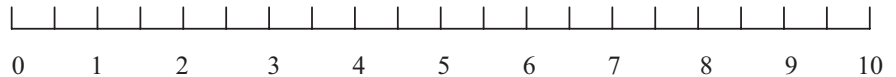
How **intense** is the pain in your leg(s) with menstruation?



How **intense** is your pain during or following intercourse?



Do you have the urge to urinate more frequently than usual?



Do you take pain medication on a regular basis? (0 = no, 10 = daily)

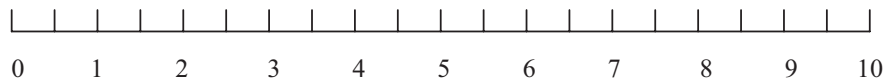


Figure. Sample VAS.

pain level compared with subsequent postprocedure course on serial follow-up. As there is currently no VAS that has been specifically validated for the pain characteristics typically described with PVI, a validated scale will need to be generated against a control popula-

tion. We recommend researchers use an objective scale similar to what has been validated for patients with cancer (35). An example of a nonvalidated VAS is found in the **Figure**. In addition, pre- and postprocedural use of a general health-related QOL question-

naire, such as the short form-12, is recommended (36). It is the authors' recommendation that reassessment with the validated VAS and a short form-12 QOL questionnaire occur at 3, 6, 12, 24, and 36 months.

Secondary endpoints for PVI treatment include technical treatment success and complications. Technical success is defined as the occlusion of diseased ovarian and internal iliac branch pelvic varices. Occlusion is confirmed by immediate postembolization venography in the parent vascular distribution of interest. All complications should be reported on a per-patient basis at standard intervals such as at 24 hours and at 30 days. Potential complications associated with embolization include infection, nontarget embolization, pulmonary embolus, and coil migration. Complications should be categorized according to a uniform standard by outcome according to severity with the Society of Interventional Radiology classification system (37) (Appendix).

COMPARISON BETWEEN TREATMENT GROUPS

Study Design

A randomized controlled clinical trial is the preferred trial design to evaluate new treatments as it minimizes bias and increases direct comparability among endovascular, surgical, and medical therapies. Randomized trials should be conducted according to Consolidated Standards of Reporting Trials guidelines (38). It is recognized that randomized trials are difficult to conduct for the evaluation of all new medical treatments and are particularly difficult to employ in the evaluation of more invasive therapies. Potential obstacles to a randomized trial include cost, patient recruitment, and ethical considerations. A staged approach to more formal PVI research may facilitate a uniform reporting standard. Initially, a multiinstitutional registry could be established. Participants would adhere to a predetermined, uniform approach to patient selection, preprocedure diagnostic evaluation, transcatheter treatment technique, and postprocedure assessment. A prospective randomized controlled clinical trial should ideally be conducted with ran-

**Table 2
Summary of PVI Reporting Standards**

Detail	Required	Recommended
Population description		
Participating institutions	×	
Patients enrolled per institution	×	
Total patient enrollment	×	
Age	×	
Ethnicity		×
Duration of symptoms	×	
Obstetrical history	×	
Ovarian point tenderness		×
Postcoital pain		×
Visible vulvar, thigh or gluteal varices		×
Details of previous treatment(s)	×	
Previous treatments per patient	×	
Time to treatment from diagnosis	×	
Pain medication use	×	
Pain assessment (validated VAS)	×	
QOL questionnaire (SF-12 QOL)		×
Inclusion/exclusion criteria	×	
Comorbidities (connective tissue disease, IBD, endometriosis, leiomyomas, ovarian cysts, PID)	×	
Cross-sectional imaging (US, CT, MR imaging, MR venography)	×	
Baseline venographic findings	×	
Other evaluations (ie, laparoscopy)		×
Method of treatment assignment	×	
Treatment description		
Venous access approach	×	
Target veins embolized	×	
Catheter(s)	×	
Embolic agent(s)	×	
Sclerosant composition	×	
Volume/amount of embolic agent and sclerosant	×	
Sedation/anesthesia	×	
Fluoroscopic time	×	
Outpatient vs inpatient care	×	
Postembolization venographic findings	×	
Primary and secondary outcomes assessment		
Technical success	×	
Pain assessment (validated VAS)	×	
QOL questionnaire (SF-12 QOL)		×
Percent of patients lost to follow-up	×	
Duration of follow-up (3, 6, 12, 24, and 36 mo)	×	
Complications classified by SIR outcome scale	×	
Costs/cost effectiveness		×

Note.—IBD = inflammatory bowel disease; PID = pelvic inflammatory disease; SF-12 = Short Form-12.

domization among medical, surgical, and endovascular therapies.

A study should be designated as single-center or multicenter and whether it is sponsored. If a study is sponsored, it should be stated whether it was performed under the direction of the United States Food and Drug Administration or another regulatory entity. The specific role of the

sponsor in funding, data management, and data analysis should be reported. Any off-label uses need to be addressed as applicable. In addition, institutional review board status must be reported.

The study design, participating institutions, number of patients enrolled per institution, overall sample size, statistical power, and statistical analy-

ses must also be reported. Primary statistical analyses should be reported based on intent to treat and per-protocol analyses. With an intent-to-treat approach, subjects are analyzed within the group to which they were randomized as to whether they received the treatment or dropped out of the study. A per-protocol analysis considers only those patients who actually received the intended treatment.

Analysis of study significance should address the study design limitations. If the study conclusions are based on analysis of surrogate outcomes, they should be tempered accordingly. Investigators should avoid drawing conclusions that are not clearly supported by the data; if alternate interpretations of the data are possible, they should also be discussed. If feasible, treatment costs, cost effectiveness, and use of resources should be tracked, analyzed, and discussed.

Control Group

Detailed information should be provided regarding the therapy against which the endovascular treatment is compared. For example, comparison versus hysterectomy or hormonal therapy should include details regarding the procedure, agent, dose, and method of administration.

CONCLUSION

Although transcatheter embolization is an established therapy for the treatment of symptomatic PVI, published series are limited by nonstandardized reporting, incomplete follow-up, and the use of variable measures of outcome. This document is an attempt to identify and document the information necessary to assure uniform reporting standards in endovascular management of PVI. A summary of recommendations for reporting is provided in **Table 2**. Standardized reporting of clinical experience facilitates understanding, enhances communication, and allows for direct comparison of clinical trial results.

Acknowledgments: Carl M. Black authored the first draft of this document and served as topic leader during the subsequent revisions of the draft. Steven F. Millward is Chair of the Technology Assess-

ment Committee. John F. Cardella is Councilor of the SIR Standards Division. Other members of the Technology Committee within SIR who participated in the development of this Reporting Standard are listed alphabetically: Steven C. Rose, MD, Mark Baerlocher, John Dean Barr, MD, John J. Borsa, MD, Matthew R. Callstrom, MD, Drew M. Caplin, MD, William B. Crenshaw, MD, Jon C. Davidson, MD, Aron Michael Devane, MD, B. Janne d'Othee, MD, Salomao Faintuch, MD, Ron C. Gaba, MD, Joseph Gemmete, MD, Debra Ann Gervais, MD, Craig B. Glaiberman, MD, S. Nahum Goldberg, MD, Marcelo S. Guimaraes, MD, Neil J. Halin, DO, Thomas B. Kinney, MD, Michael D. Kuo, MD, John A. Lippert, MD, Llewellyn V. Lee, MD, Ashish Mahajan, MD, Rahmi Oklu, MD, PhD, Dheeraj K. Rajan, MD, Stefanie M. Rosenberg, PA, James E. Silberzweig, MD, Richard Towbin, MD, Michael J. Wallace, MD, Curtis W. Bakal, MD, Curtis A. Lewis, MD, MBA, JD, and Kenneth S. Rholl, MD.

APPENDIX: SIR STANDARDS OF PRACTICE COMMITTEE CLASSIFICATION OF COMPLICATIONS BY OUTCOME

Minor Complications

- A. No therapy, no consequence.
- B. Nominal therapy, no consequence; includes overnight admission for observation only.

Major Complications

- C. Require therapy, minor hospitalization (< 48 h).
- D. Require major therapy, unplanned increase in level of care, prolonged hospitalization (> 48 h).
- E. Permanent adverse sequelae.
- F. Death.

References

1. Robinson JC. Chronic pelvic pain. *Curr Opin Obstet Gynecol* 1993; 5:740–743.
2. Kim HS, Malhotra AD, Lee ML, Venbrux AC. Embolotherapy for pelvic congestion syndrome: long-term results. *J Vasc Interv Radiol* 2006; 17:289–297.
3. Richet MA. *Traite pratique d'anatomie medico-chirurgicale* [Treatise on practical medical-surgical anatomy]. Paris: Balliere et fils, 1857.
4. Taylor HC. Vascular congestion and hyperemia; their effects on structure and function in the female reproduc-

tive system. *Am J Obstet Gynecol* 1949; 57:637–653.

5. Benson R, Hanson K, Matarazzo J. Atypical pelvic pain in women: gynecologic psychiatric considerations. *Am J Obstet Gynecol* 1959; 77:806–825.
6. Duncan CH, Taylor HC Jr. A psychosomatic study of pelvic congestion. *Am J Obstet Gynecol* 1952; 64:1–12.
7. Hobbs JT. The pelvic congestion syndrome. *Practioner* 1976; 41:41–46.
8. Hobbs JT. Varicose veins arising from the pelvis due to ovarian vein incompetence. *Int J Clin Pract* 2005; 59:1195–1203.
9. Farquhar CM, Rogers V, Franks S, et al. A randomized controlled trial of medroxyprogesterone acetate and psychotherapy for the treatment of pelvic congestion. *Br J Obstet Gynaecol* 1989; 96:1153–1162.
10. Soysal ME, Soysal S, Vicdan K, Ozer S. A randomized controlled trial of goserelin and medroxyprogesterone acetate in the treatment of pelvic congestion. *Hum Reprod* 2001; 16:931–939.
11. Beard RW, Kennedy RG, Gangar KF, et al. Bilateral oophorectomy and hysterectomy in the treatment of intractable pelvic pain associated with pelvic congestion. *Br J Obstet Gynaecol* 1991; 98:988–992.
12. Carter J. Surgical treatment for chronic pelvic pain. *J Soc Laparoendosc Surg* 1998; 2:129–139.
13. Edwards RD, Robertson JR, MacLean AB, Hemingway AP. Case report: pelvic pain syndrome—successful treatment of a case by ovarian vein embolization. *Clin Radiol* 1993; 47:429–431.
14. Sichlau MF, Yao JS, Vogelzang RL. Transcatheter embolotherapy for the treatment of pelvic congestion syndrome. *Obstet Gynecol* 1994; 83:892–896.
15. Tarazov PG, Prozorovskij KV, Ryzhkov VK. Pelvic pain syndrome caused by ovarian varices: treatment by transcatheter embolization. *Acta Radiol* 1997; 38:1023–1025.
16. Capasso P, Simons C, Trotteur G, Dondelinger RF, Henroteaux D, Gaspard U. Treatment of symptomatic pelvic varices by ovarian vein embolization. *Cardiovasc Intervent Radiol* 1997; 20:107–111.
17. Cordts PR, Eclavea A, Buckley PJ, DeMaiores CA, Cockerill ML, Yeager TD. Pelvic congestion syndrome: early clinical results after transcatheter ovarian vein embolization. *J Vasc Surg* 1998; 28:862–868.
18. Maleux G, Stockx L, Wilms G, Marchal G. Ovarian vein embolization for the treatment of pelvic congestion syndrome: long-term technical and clinical results. *J Vasc Interv Radiol* 2000; 11:859–864.

19. Venbrux AC, Chang AH, Kim HS, et al. Pelvic congestion syndrome (pelvic venous incompetence): impact of ovarian and internal iliac vein embolotherapy on menstrual cycle and chronic pelvic pain. *J Vasc Interv Radiol* 2002; 13: 171–178.
20. Pieri S, Agresti P, Morucci M, de'Medici L. Percutaneous treatment of pelvic congestion syndrome. *Radiol Med (Torino)* 2003; 105:76–82.
21. Bachar GN, Belenky A, Greif F, et al. Initial experience with ovarian vein embolization for the treatment of chronic pelvic pain syndrome. *Isr Med Assoc J* 2003; 12:843–846.
22. Ignacio EA, Sarin S, Harper A, et al. Pelvic congestion syndrome: diagnosis and treatment. *Semin Interv Radiol* 2009; 25:361–368.
23. Chung MH, Huh CY. Comparison of treatments for pelvic congestion syndrome. *Tohoku J Exp Med* 2003; 201: 131–138.
24. Hobbs JT. The pelvic congestion syndrome. *Br J Hosp Med* 1990; 43:200–206.
25. Beard RW, Reginal PW, Wadsworth J. Clinical features of women with chronic lower abdominal pain and pelvic congestion. *Br J Obstet Gynaecol* 1988; 95:153–161.
26. Sutaria R, Subramanian A, Burns B, Hafex H. Prevalence and management of ovarian venous insufficiency in the presence of leg venous insufficiency. *Phlebology* 2007; 22:29–33.
27. Black CM, Collins J, Hatch D, et al. Pelvic venous congestion syndrome and lower extremity superficial venous reflux disease. *J Vasc Interv Radiol* 2005; 16(Suppl):S123.
28. Kennedy A, Hemingway A. Radiology of ovarian varices. *Br J Hosp Med* 1990; 44:38–43.
29. Stones RW. Pelvic vascular congestion-half a century later. *Clin Obstet Gynecol* 2003; 46:831–836.
30. Beard RW, Highman JH, Pearce S, et al. Diagnosis of pelvic varicosities in women with chronic pelvic pain. *Lancet* 1984; 2:946–949.
31. Park SJ, Lim JW, Ko YT, et al. Diagnosis of pelvic congestion syndrome using transabdominal and transvaginal sonography. *AJR Am J Roentgenol* 2004; 182:683–688.
32. Umeoka S, Koyama T, Togashi K, et al. Vascular dilatation in the pelvis: identification with CT and MR imaging. *Radiographics* 2004; 24:193–208.
33. Desimpelaere JH, Seynaeve PC, Hagers YM, Appel BJ, Mortelmans LL. Pelvic congestion syndrome: demonstration and diagnosis by helical CT. *Abdom Imaging* 1999; 24:100–102.
34. Stein B, Sussman S, Illescas F, Straub J, Vine H, Ohki S. 3D gadolinium enhanced magnetic resonance venography as a potential modality to screen for incompetent gonadal veins in patients suspected of having pelvic congestion syndrome (abstr.). *J Vasc Interv Radiol* 2000; 11(Suppl):S221–S222.
35. Grossman SA, Sheidler VR, McGuire DB, Geer C, Santor D, Piantadosi S. A comparison of the Hopkins pain rating instrument with standard visual analogue and verbal descriptor scales in patients with cancer pain. *J Pain Symptom Manage* 1992; 7:196–203.
36. Ware J, Kosinski M, Keller S. How to score the SF-12 physical and mental health summary scales, 3rd ed. Lincoln, RI: Quality Metric, 1998.
37. Sacks D, Marinelli DL, Martin LG, Spies JB. Reporting standards for clinical evaluation of new peripheral arterial revascularization devices. *J Vasc Interv Radiol* 2003; 14(Suppl):S395–S404.
38. Begg C, Cho M, Eastwood S, et al. Improving the quality of reporting randomized controlled trials. The CONSORT Statement. *JAMA* 1996; 276:637–630.